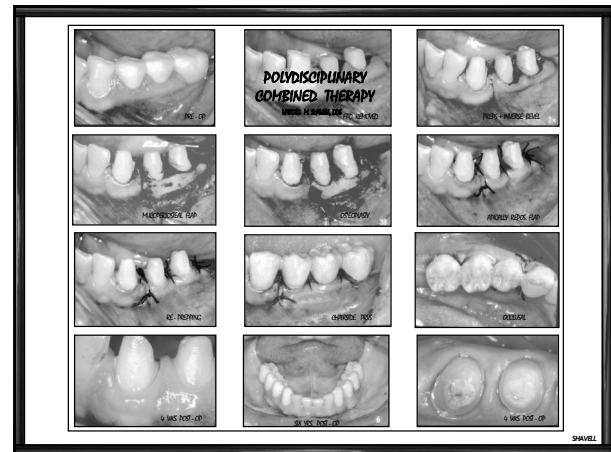


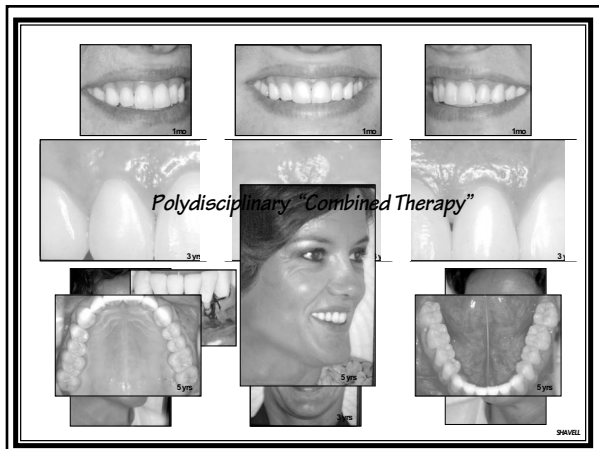
Walking In The Steps Of Dr. Harold M. Shavell

***Utilizing “Combined
Therapy”..... A Perioprosthetic
Approach To Restorative Dentistry***

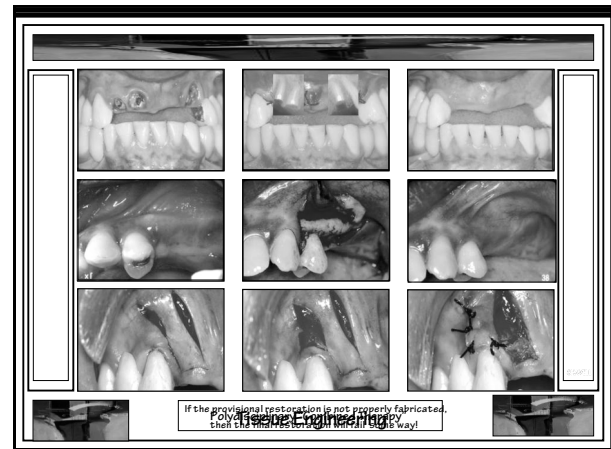
38



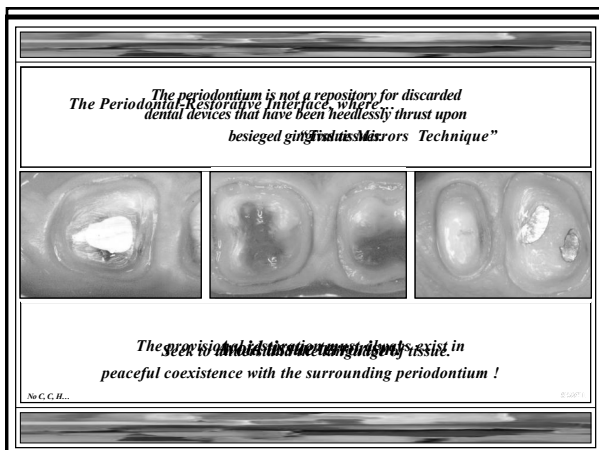
39



40



41

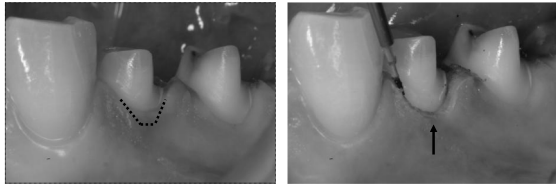


42

“Perio By The Numbers”

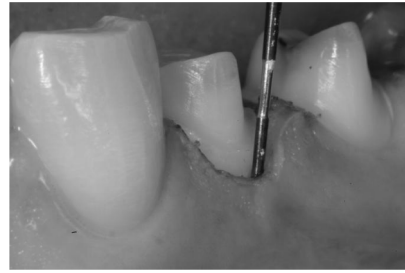
***Predictable Restorative Margin
Placement Based On Biologic
Width And Sounding To The
Crest Of The Alveolar Bone***

43



Is There An Adequate Amount Of Attached Gingiva Beyond The "Corrected" Free Gingival Margin?

44



***Will The Gingival Tissue Grow Back To The Preoperative Position?
Bony Crest MUST Be 3mm Apical To The Corrected Free Gingival Margin For A Stable Result***

45

The "Magic" Numbers – The Distance Of The Restorative Margin (Equicrevicular) To The Bony Crest

Dr. Frank Spear / Dr. John Kois

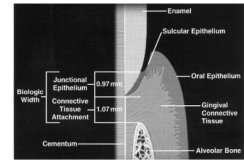
***Anterior Teeth:
Facial (Lingual) Aspect = 3 millimeters
Interproximal Aspect = 4 millimeters***

***Posterior Teeth:
Facial, Lingual, and Interproximal Aspect
= 3 millimeters***

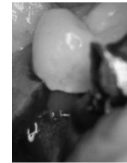
46

The Tooth-Restorative Interface

***Normal Crest (70% patients)
2 mm combined
epithelial/connective tissue
attachment***

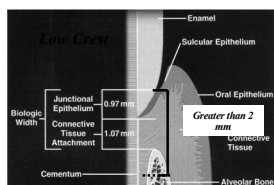


***Wentz, Orban,
Garguilo Biologic
Width Model - 1967***

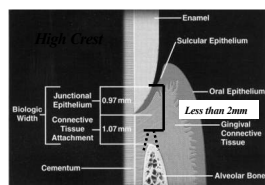


47

The Tooth-Restorative Interface

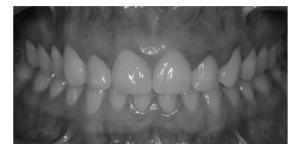
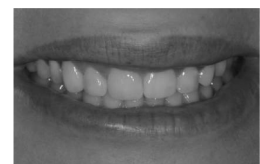
***Low Crest: Greater than 2mm
combined epithelial/connective
tissue attachment. Highly
susceptible to gingival
recession***

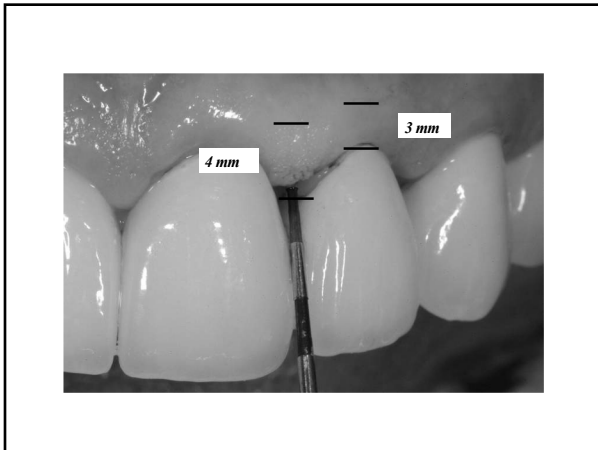


***High Crest: Less than 2mm
combined
epithelial/connective tissue
attachment. Highly resistant
to gingival recession***

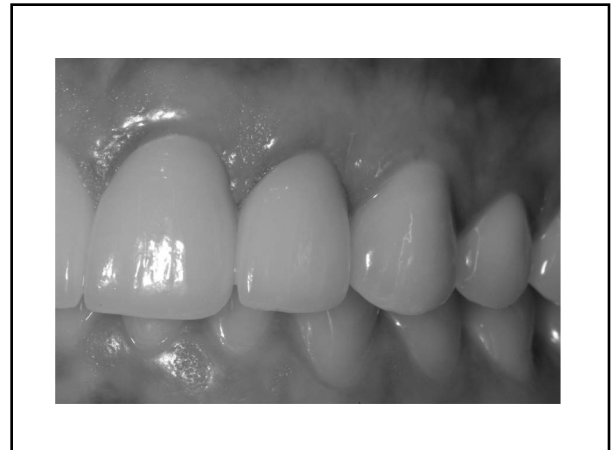48



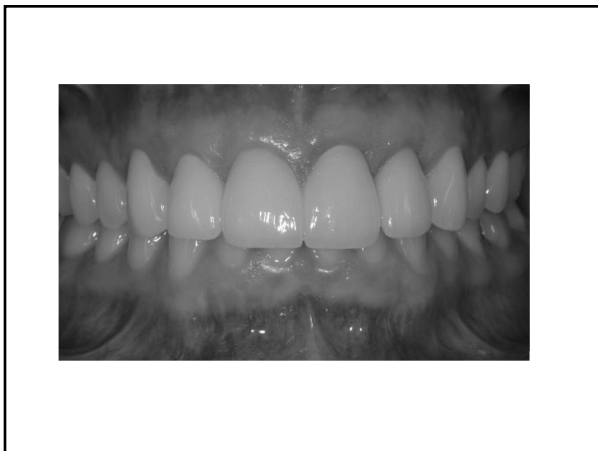49



50



51



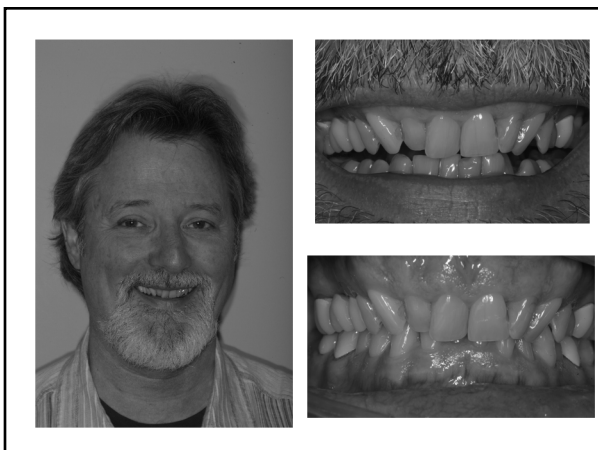
52

***Walking In The Steps Of
Dr. Harold M. Shavell***

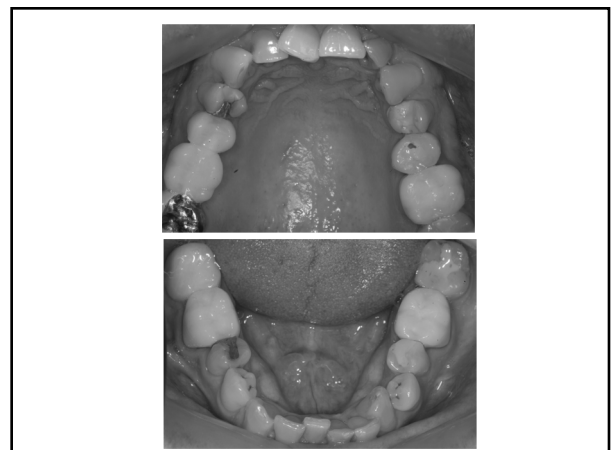
***Class I Dentally Compensated
Class II Malocclusion***

***“When The Cure Is Worse
Than The Disease!”***

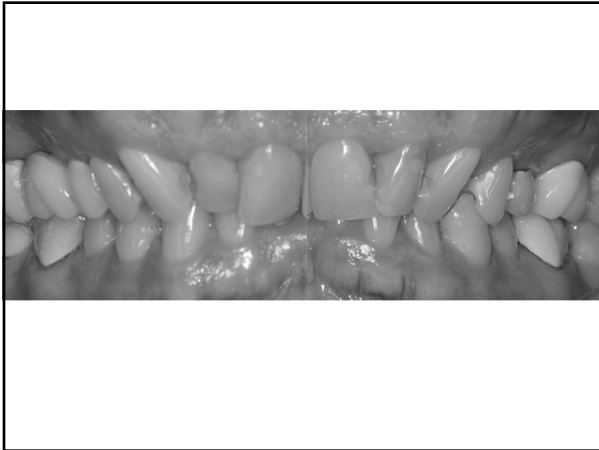131



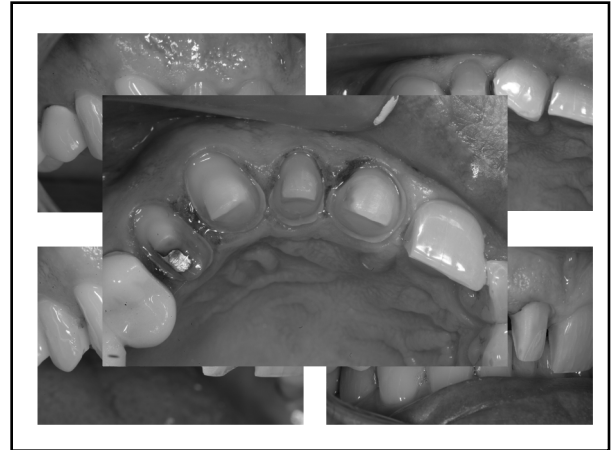132



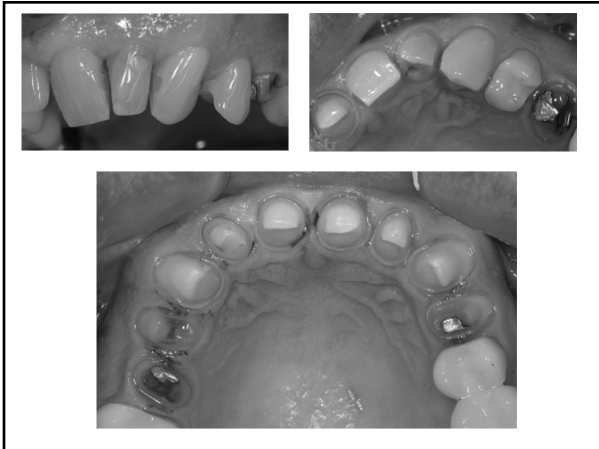133



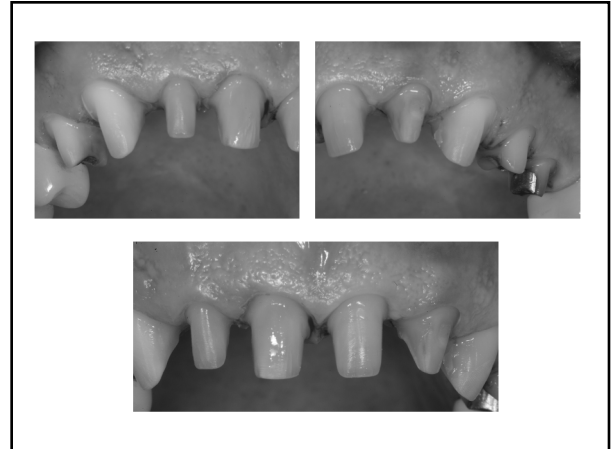134



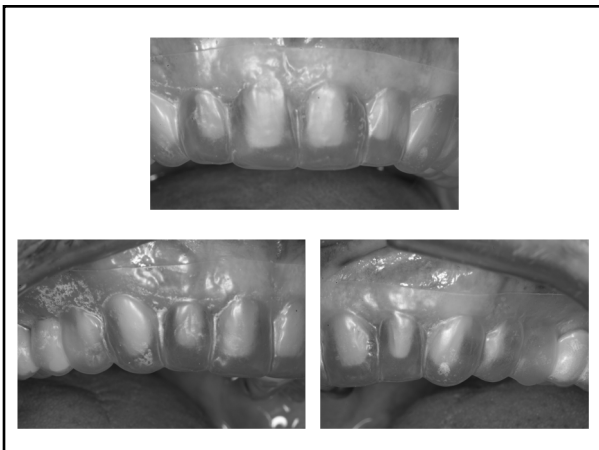135



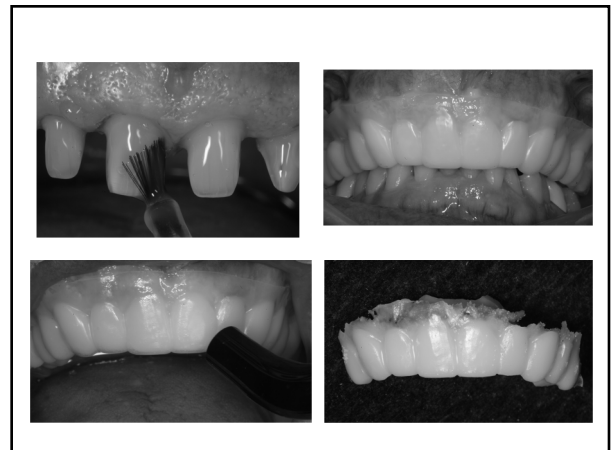
136



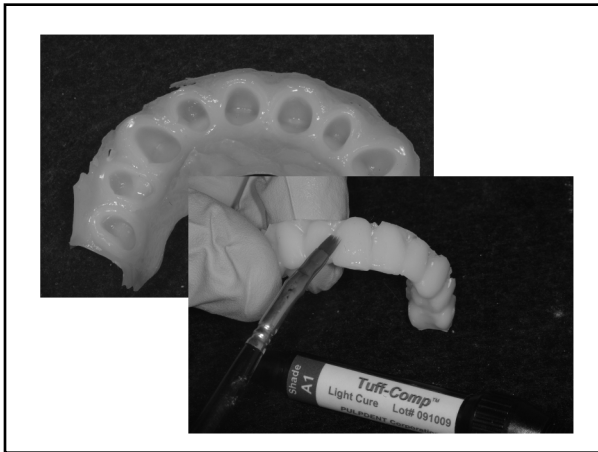
137



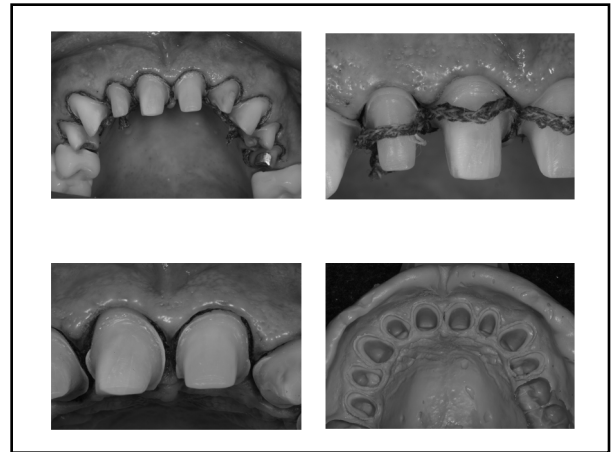
138



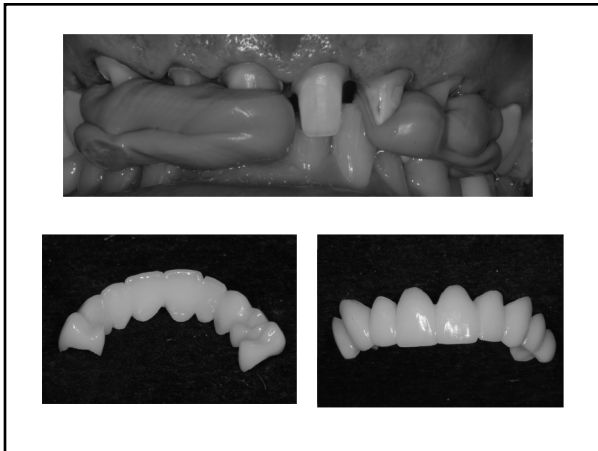
139



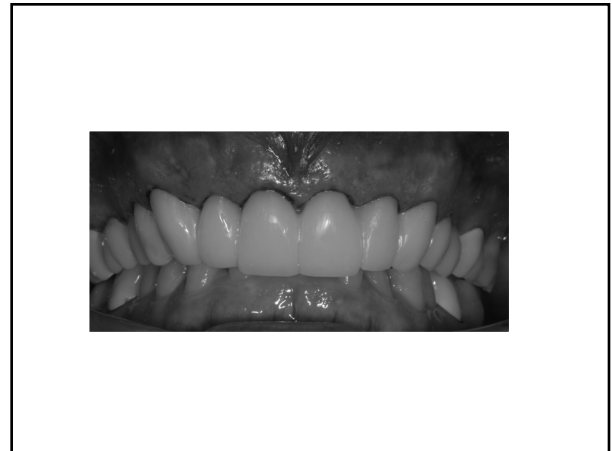
140



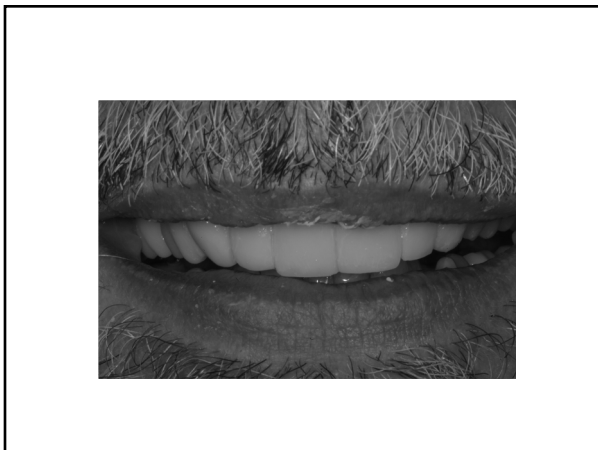141



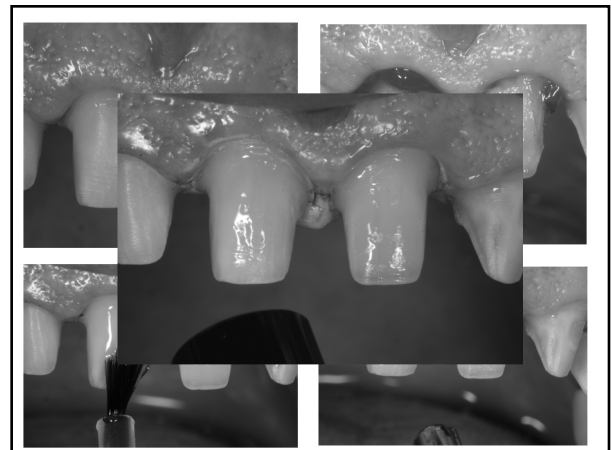
142



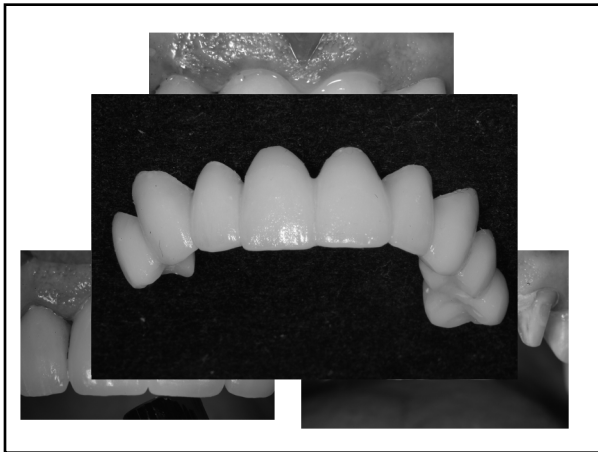
143



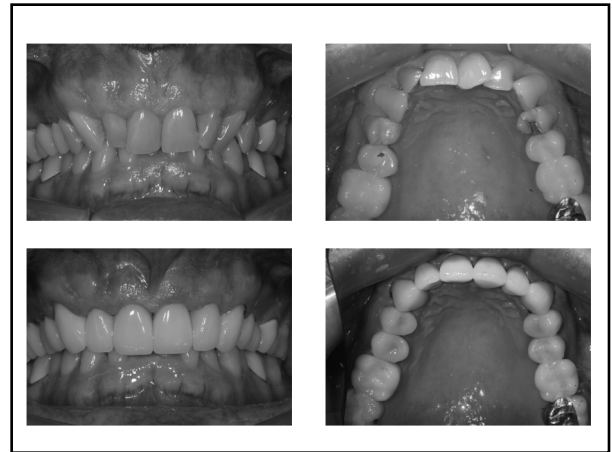
144



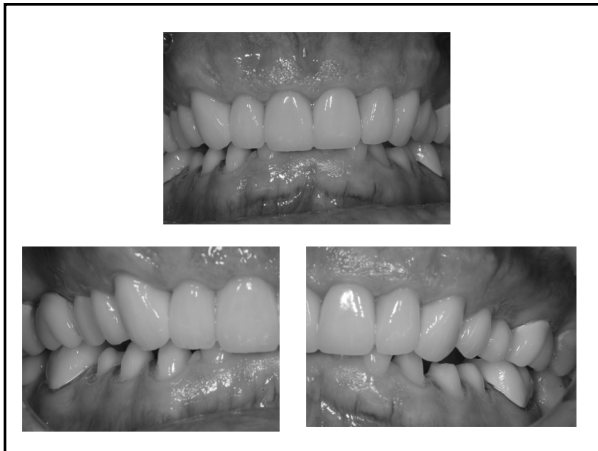
145



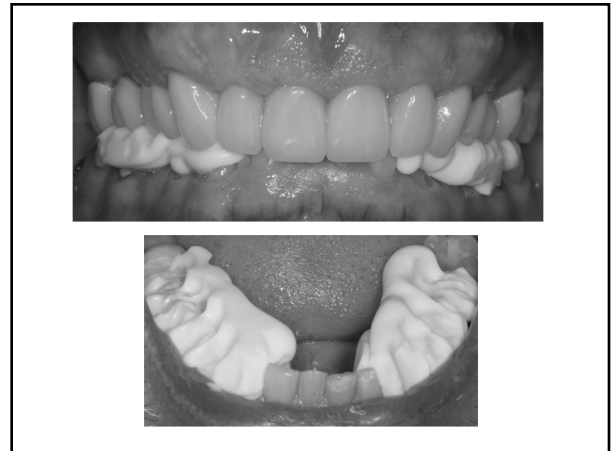146



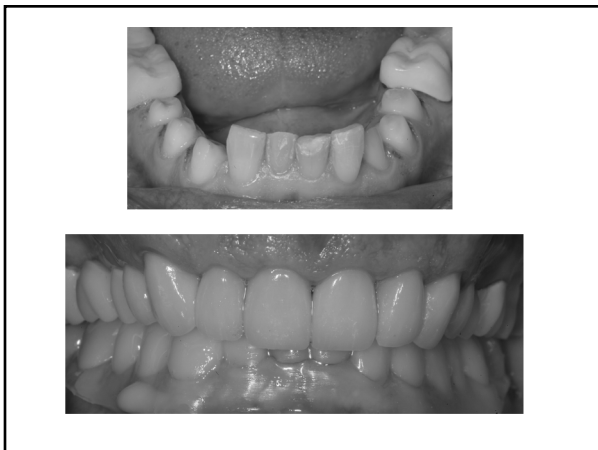
147



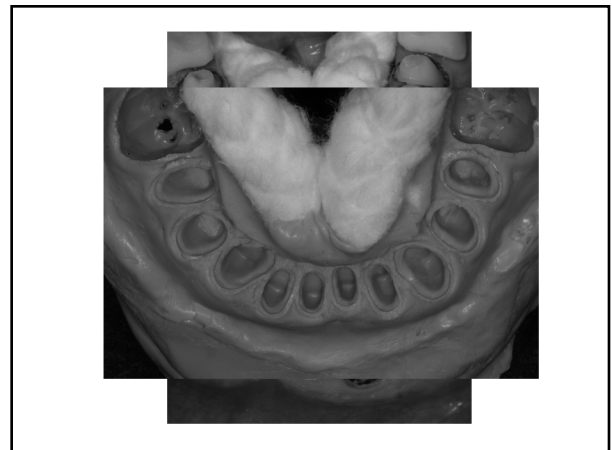
148



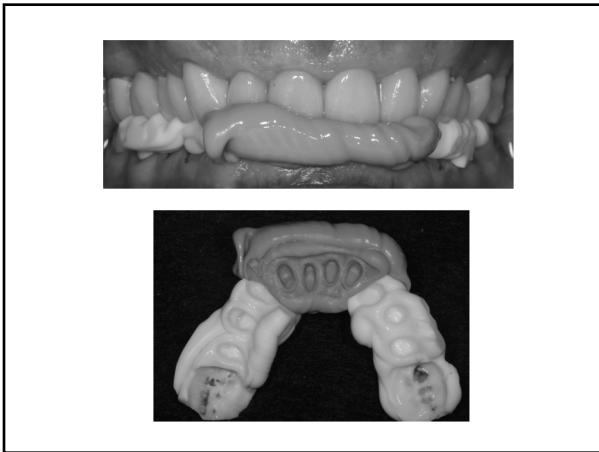
149



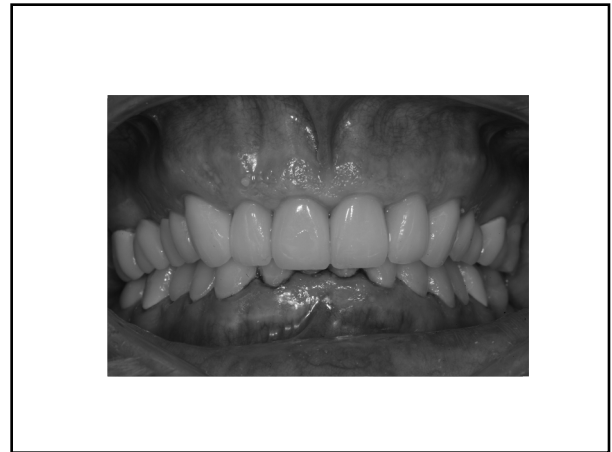150



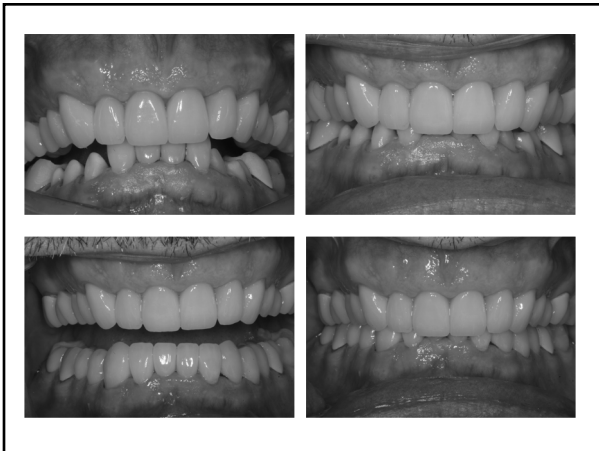
151



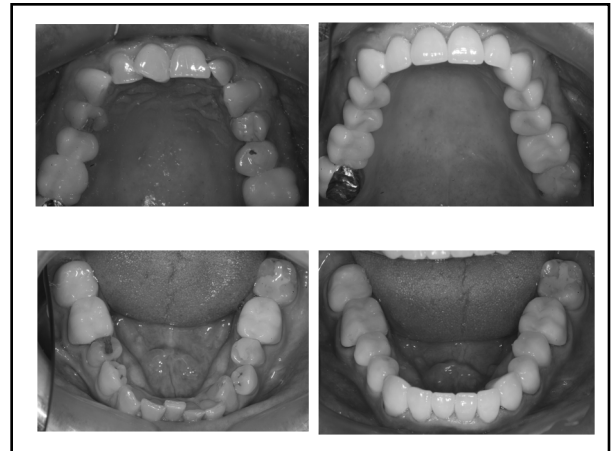
152



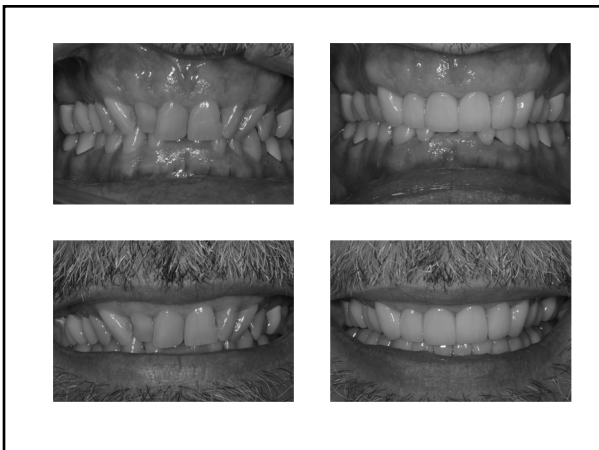
153



154



155



156



157

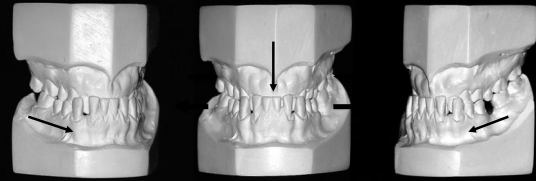
***Walking In The Steps Of
Dr. Harold M. Shavell***

“Instant Orthognathics”

***When Surgery and Orthodontics
Is Not A Treatment Option***

158

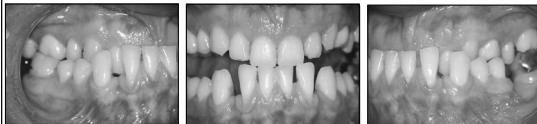Class III Malocclusion



(Frontal / Horizontal / Saggital Deviations)

159

THINK: EMPIRICISM RESTRAINED BY REASON...

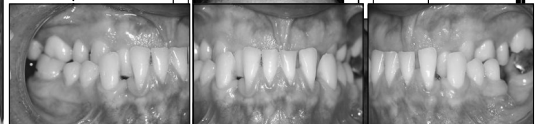

...AND POLYDISCIPLINARY THERAPY.
(WHERE 'ALMOST' PROVES ENOUGH)

160

THE HIGHEST EXCELLENCE IN OCCLUSION IS ACHIEVING AND MAINTAINING
SYNCHRONOUS POSTERIOR INTERCUSPATION AS WELL AS SALUTARY ANTERIOR
GUIDANCE COUPLED WITH THE TERM...

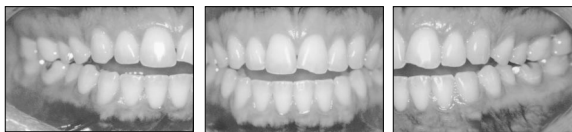BIOMECHANICAL



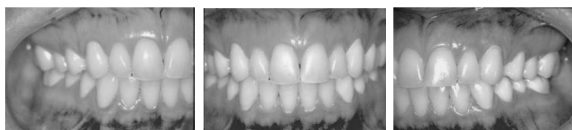There is a proper place for each tooth, wherein all of the biomechanical and physiological forces acting upon it are reciprocated and in complete occlusal harmony.

161

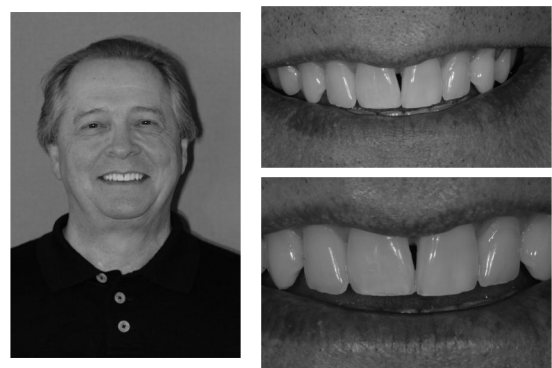CLASS I ANTERIOR OPEN-BITE MALOCCLUSION: FINAL RESULTS



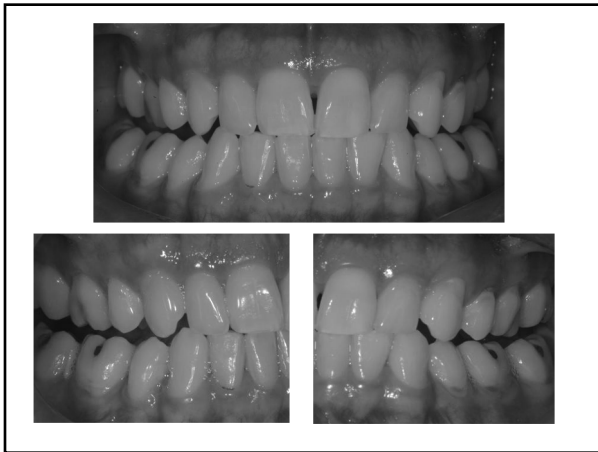***GIVEN THE PATIENT'S AVERSION TO ORTHOGNATHICS,
HOW WOULD YOU HAVE TREATED THIS CASE ??***



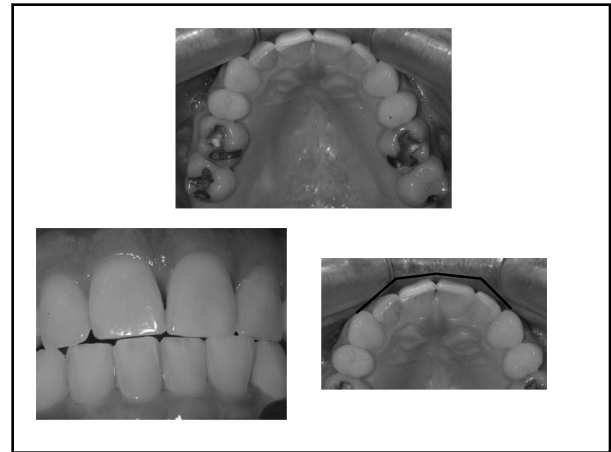
162



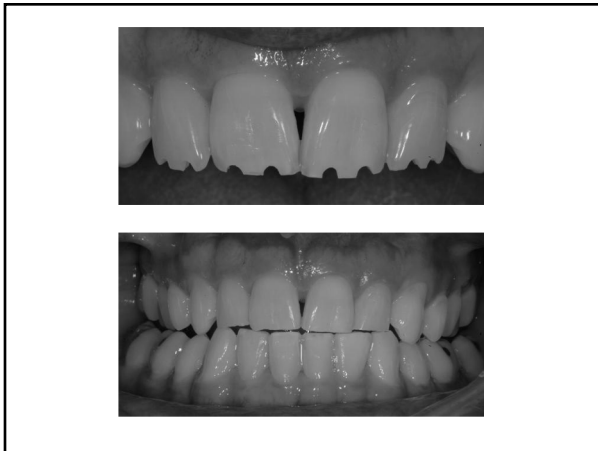
163



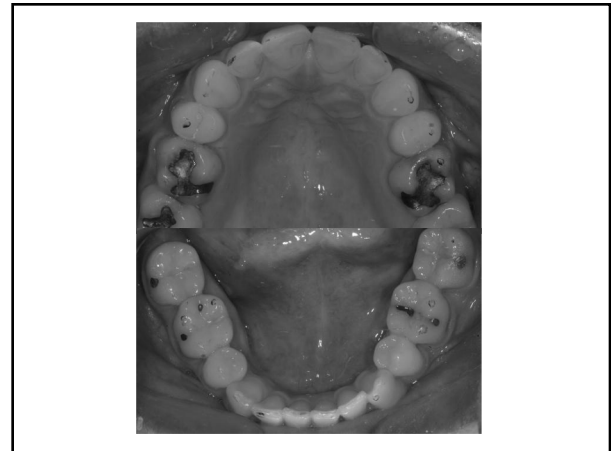164



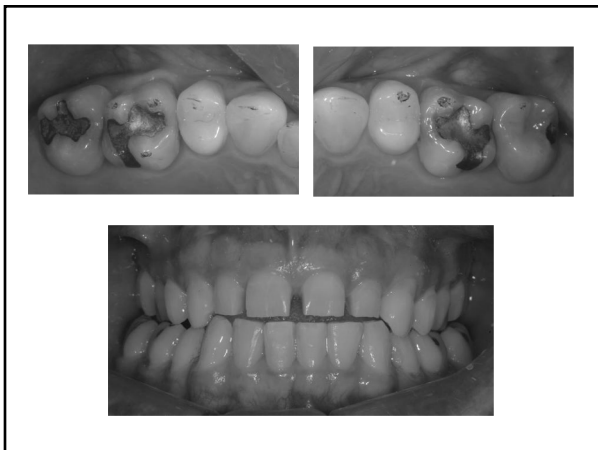165



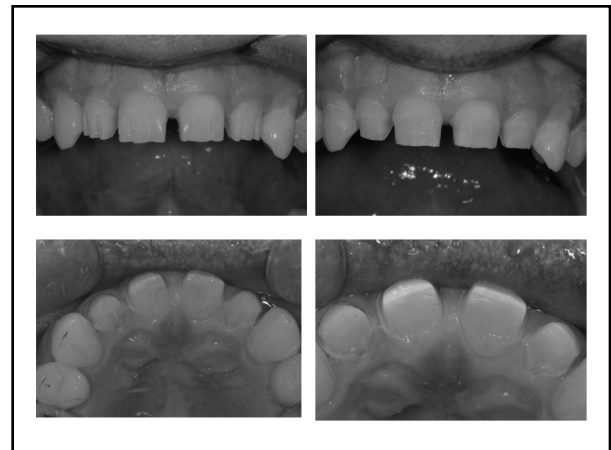
166



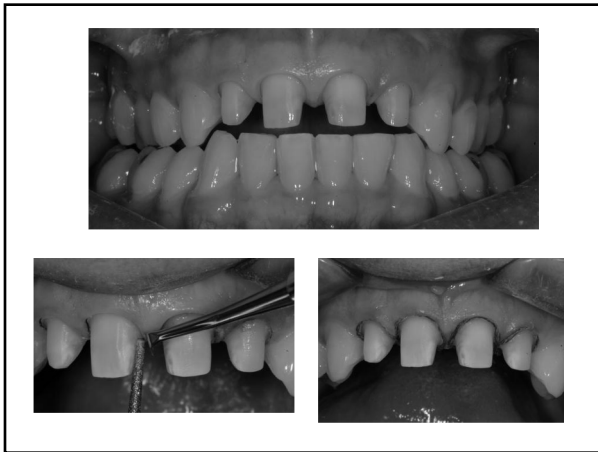167



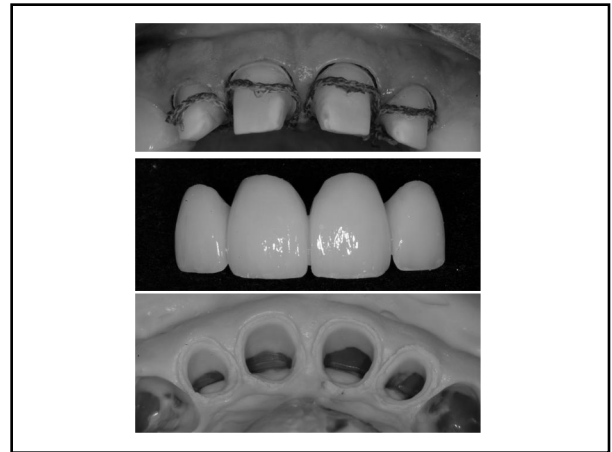
168



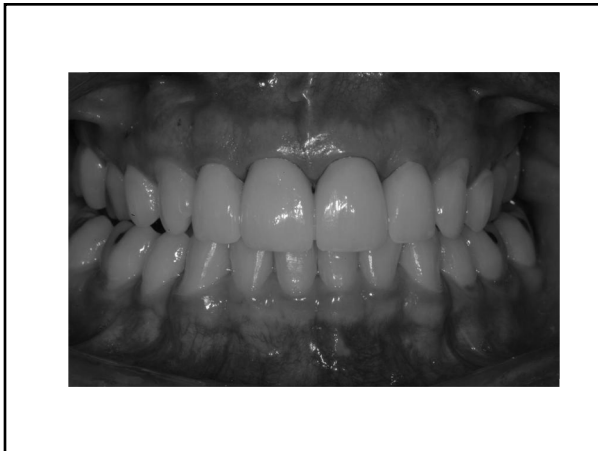169



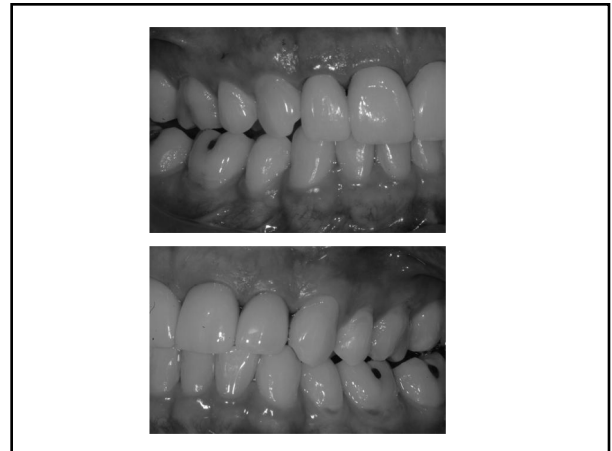170



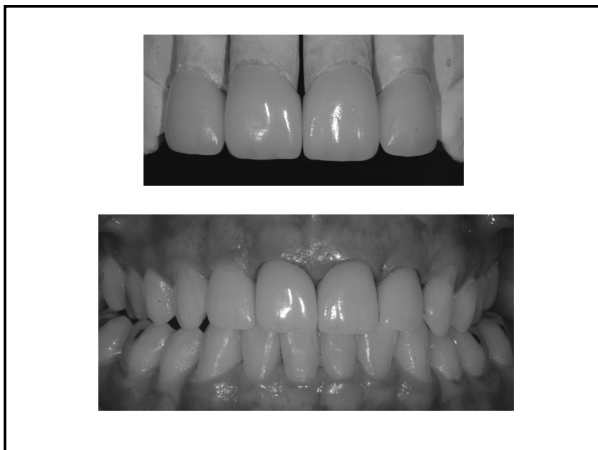171



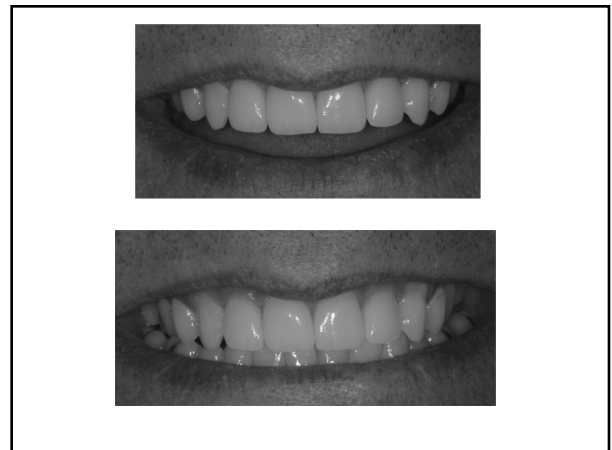
172



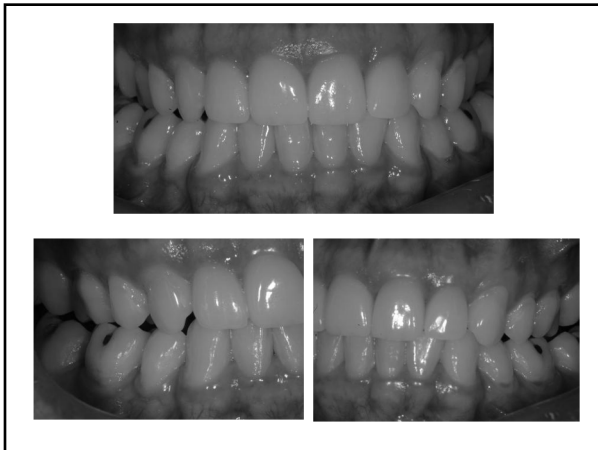
173



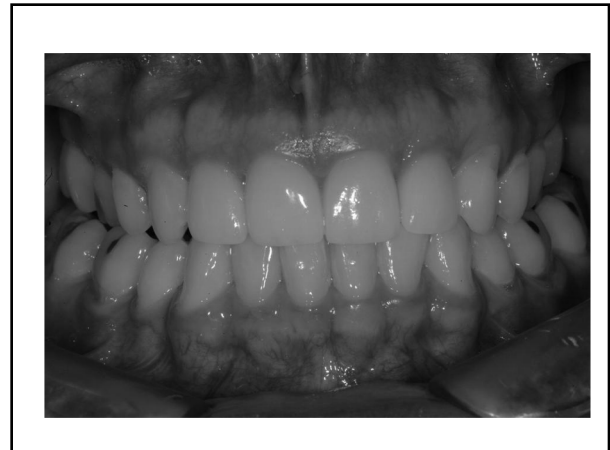
174



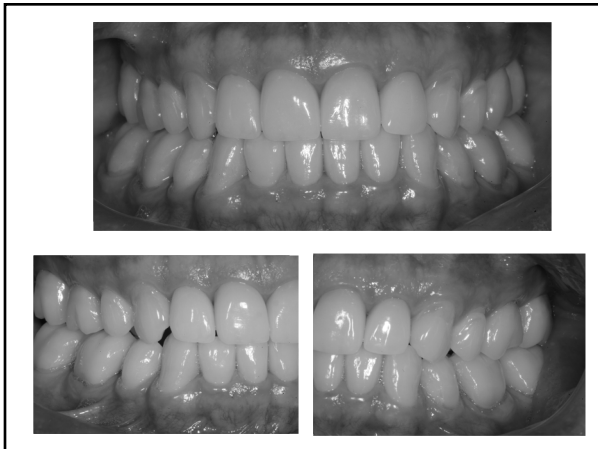175



176



177



178

Visit Me On My...

www.CatapultEducation.com

Catapult University Classroom

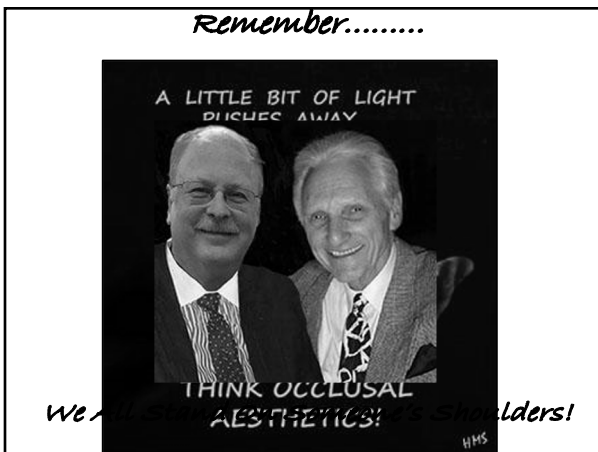


- ☐ Course notes, Articles, Clinical Videos, and Information
- ☐ Case of the Month (Coming!)
- ☐ New Product information and Seminar Specials
- ☐ Discussion Blog (Coming!)

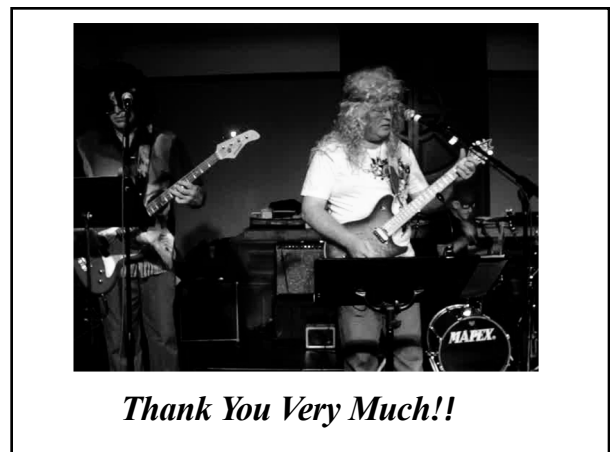Complete information on Sign In Sheet and check

"Opt In"

197



198



199